

## Anaesthetic Management of a Case of Mediastinal Mass : A Case Report

- Dr. MADHURI S KURDI<sup>1</sup>      ■ Dr. SAFIYA SHAIKH<sup>2</sup>  
 ■ Dr. SHEETAL HIREGOUDAR<sup>3</sup>   ■ Dr. R. ASHWINI HALES<sup>4</sup>  
 ■ Dr. ANJALI KUMARI. B.<sup>5</sup>

### SUMMARY :

Anterior mediastinal masses are uncommon, and when they present at surgery for diagnostic or for definitive procedures, they pose serious challenges for the anaesthesiologist. We present here, the anaesthetic & peri-operative management of a case of anterior mediastinal mass.

### INTRODUCTION :

Tumours presenting in and around the mediastinal cavity are uncommon.<sup>1,2</sup> The commonly encountered mediastinal masses by the anaesthesiologist are the lesions located in the anterosuperior mediastinum like lymphomas, teratomas, lymphoblastic leukemia, cystic hygroma, bronchogenic cyst etc.<sup>3</sup> Anterior mediastinal tumours can be very difficult to manage in the peri-operative period and there are many reports of peri-operative cardiorespiratory disasters & even death related to these cases.<sup>2,4,5</sup>

### CASE REPORT :

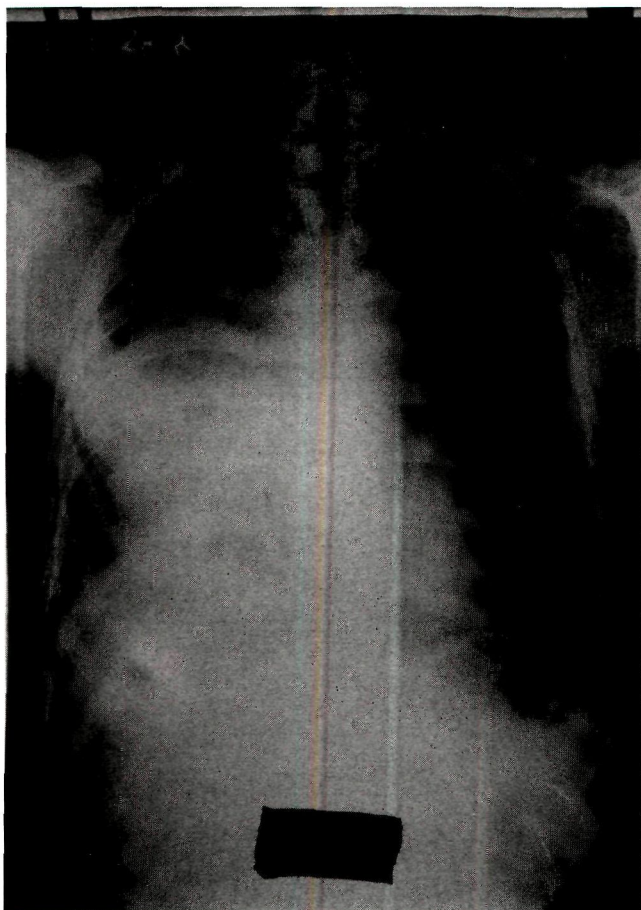
A 21 yr old male patient weighing 46 kg presented to us for thoracotomy & excision of an anterior mediastinal mass. He had history of cough with copious amount of mucoid secretion since 1½ months, & grade 2 dyspnoea. The cough was aggravated on lying down posture & especially in left lateral posture. Symptoms were not relieved with medication. He had history of weight loss since 2 months & disturbed sleep because of cough. There was no history of orthopnea, stridor, dysphagia, headache, edema. On examination, vital signs were normal. Chest expansion & air entry were markedly decreased and dull note on percussion was noted over right anterior chest over mammary, infra mammary & infra

1. M.D., Professor, Dept of Anaesthesiology, Karnataka Institute of Medical Sciences , Hubli
2. M.D., Professor & HOD, Dept of Anaesthesiology, Karnataka Institute of Medical Sciences , Hubli
3. D.A., Sr Resident, Dept of Anaesthesiology, Karnataka Institute of Medical Sciences , Hubli
4. P G Student, Dept of Anaesthesiology, Karnataka Institute of Medical Sciences , Hubli
5. P G Student, Dept of Anaesthesiology, Karnataka Institute of Medical Sciences , Hubli

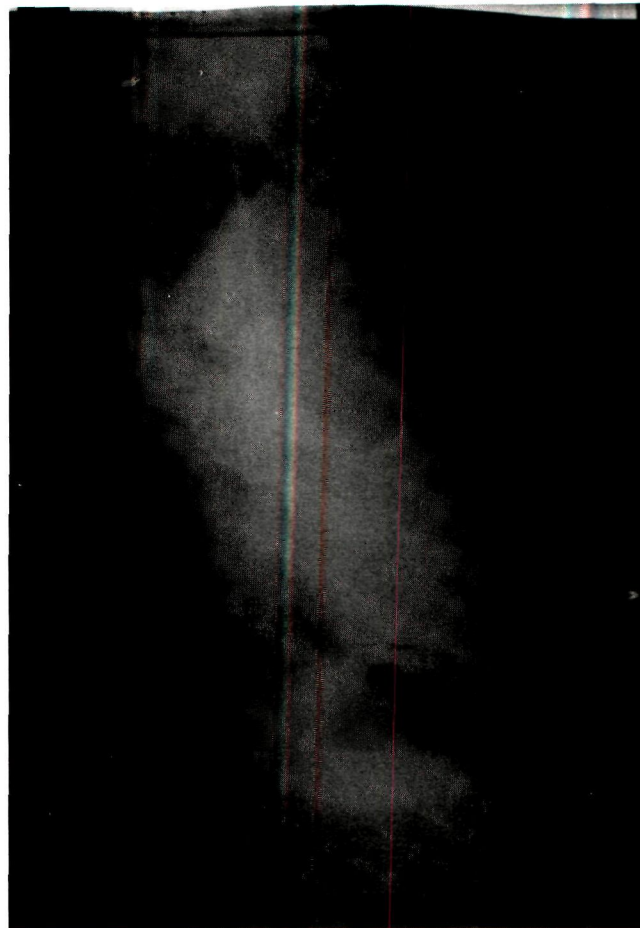
Corresponding author – Dr. Madhuri S Kurdi, Professor, Dept. of Anaesthesiology, KIMS, Hubli

Email : drmadhuri\_kurdi@yahoo.com      Mobile no. - 9449590556

axillary areas. Diffuse rhonchi & crepitations were heard over right mammary & inframammary areas. Rest of the systemic examination was normal. All his basic investigations were normal. Chest X-ray revealed right sided pleural effusion with collapse of right middle & lower lobes. USG chest revealed signs of right sided empyema. CT scan chest showed features of anterior mediastinal mass measuring 136×111mm compressing the right middle & lower lobe bronchi, the cardia & great vessels of the mediastinum. Right sided pleural effusion was also noted. The mediastino-thoracic ratio was 15.4-21cm. the mediastino mass ratio 15.4-11.5cm, tracheal cross-sectional area 16mm side to side & 17mm anteroposterior i.e, there was no evidence of tracheal compression. ECG & echocardiography were normal. Because of severe cough, patient was not able to perform PFTs including PEFr, spirometry & bedside PFTs except breath holding time which was 10 seconds.



**PA view of CXR (pre-operative)**



**Lateral view of CXR(pre-operative)**

Pre-operative sedation was avoided. IV glycopyrrolate 0.2mg was given. Baseline SaO<sub>2</sub> on room air was 99% in all positions. Epidural catheter was inserted at T7-T8 interspace. Patient was induced with titrated doses of IV thiopentone sodium 5mg/kg. Ventilation with face mask was tried & was successful. Succinylcholine IV 1.5mg/kg was given. Endotracheal intubation was done with left sided double lumen tube(37Fr). Air entry was checked & tube was fixed. 18 G CVP line was inserted through right internal jugular vein. Patient was maintained on oxygen, nitrous Oxide , intermittent halothane & vecuronium. Intraoperatively SaO<sub>2</sub>, EtCO<sub>2</sub>, pulse, BP, urine output, CVP, temperature were monitored throughout & were maintained. The duration of surgery was 3 hours. Postoperatively the patient was put on elective mechanical ventilation in ICU for 24 hours & was then extubated. Postoperative analgesia was provided with epidural 0.125% bupivacaine & 150 µg buprenorphine at 8 hourly intervals. The rest of

the postoperative period was uneventful. HPE revealed the mass to be a benign cystic teratoma.

## DISCUSSION :

Mediastinal masses can compress the major airways, so patients should be evaluated carefully before subjecting them to anaesthesia.<sup>3</sup> Even large mediastinal masses can present without any clinical symptoms of airway compression.<sup>3</sup> A number of asymptomatic patients have developed severe airway obstruction & respiratory distress during induction of anaesthesia, intubation & also during emergence after extubation.<sup>6</sup> Nevertheless, pre-operative assessment of the patient's airway at the bedside,<sup>6</sup> history related to symptoms of airway obstruction like cough, breathlessness, exacerbation on exertion or at rest & in different postures,<sup>4</sup> stridor, dyspnoea, orthopnea should be elicited from the patient & his relatives.<sup>3</sup> History of headache, facial & arm edema suggesting SVC obstruction & history of dysphagia, esophageal compression should be elicited.<sup>4</sup> One should look for cyanosis, wheeze & reduced air entry, neck vein distension in different positions of patients.<sup>4</sup> The radiological evaluation of airway should include

1. Penetrated X-ray neck- AP & lateral view to detect trachea bronchial compression.
2. PA & lateral views of chest X-ray- for location of mass & its relation to trachea bronchial tree, compression & deviation of airway, lung collapse.
3. CT scan of chest to quantify the degree of airway compression, evaluation of lower airways i.e, the main bronchi, measurement of airway diameter, tracheal cross sectional area, mediastino-thoracic ratio (MTR), mediastino-mass ratio (MMR).<sup>3</sup>
4. PFT including PEFV & flow volume loops in supine & upright positions to identify patients at risk.<sup>3</sup>

ECG & echocardiography should be done to detect the invasion of heart & pericardium by the mass. We conducted a thorough pre-operative

assessment including a detailed history, physical examination & investigations including chest X-ray, CT scan, ECG & echocardiography & PFT. 35-50% decrease in diameter of tracheo-bronchial lumen, patients with less than 50 % of predicted tracheal crosssectional area, mediastino-thoracic ratio more than 50 %, mediastino mass ratio more than 56 %, mixed (obstructive & restrictive) abnormality pattern<sup>7</sup> on PFT are associated with significant peri-operative respiratory complications.<sup>3</sup> After a thorough evaluation & interdepartmental discussion, we made an optimal anaesthetic plan for the thoracotomy. As Dutt & Tempe<sup>3</sup> have suggested, since there was not much evidence of major airway obstruction in our case we did an IV induction with titrated dose of thiopentone. After documentation of airway patency by bag & mask ventilation, the short acting muscle relaxant, succinyl choline was used to help endotracheal intubation. IPPV was clearly possible & hence the longer acting muscle relaxant vecuronium was administered till the procedure was completed. However if the patient has evidence of airway obstruction, a more careful approach with awake fiberoptic intubation or induction & intubation under deep inhalational anaesthesia with fiberoptic bronchoscopy, emergency tracheostomy set, rigid bronchoscope, double lumen tubes, cardiopulmonary bypass readily available to manage emergency airway obstruction is needed.<sup>1,3</sup>

Many intra-operative complications like inability to ventilate, severe pulmonary shunt (SaO<sub>2</sub> < 95%) at FiO<sub>2</sub> 100, hemodynamic instability including hypotension, bradycardia, tachycardia have been reported.<sup>7</sup> Post-operative complications include respiratory distress, post obstruction pulmonary edema, pneumonia, airway edema, atelectasis & pericardial effusion.<sup>7</sup> Excepting a brief period of intra-operative hypotension which responded to vasopressors we fortunately did not encounter any of these complications.

**CONCLUSION :**

A thorough pre-anaesthetic assessment including history, physical examination & evaluation by specific investigations is very important in case of mediastinal mass. Radiological investigations like chest X-ray, CT scan & MRI should be done not only to evaluate the tumour but also the airway. The

anaesthesiologists should always be prepared to deal with an emergency even in patients who have no evidence of airway obstruction. A team consisting of an ENT surgeon, cardiac surgeon, cardiopulmonary bypass personnel & a senior expert anaesthesiologist are necessary for a successful management of a case of anterior mediastinal mass.

**REFERENCES :**

1. Goh M H, Liu X Y, Gho Y S. Anterior mediastinal masses : an anesthetic challenge *Anaesthesia* 1999;54:670-682
2. John W W Gothard. Anaesthetic considerations for patients with anterior mediastinal masses. *Anesthesiology clinics* 2008; 26:305-314
3. Vishnu Dutt, Deepak K Tempe. Airway management in patients with mediastinal masses. *IJA* 2005; 49(4): 344-352
4. Navneet Narula et al. Intraoperative life threatening airway obstruction in a patient with mediastinal mass. *IJA* 2006;50(3):214-217
5. Ronald R Miller. The anaesthetic management of the patient with an anterior mediastinal mass. *Anesthesiology* 1984;60:144-147
6. Pullerits J, Holzman R. Anaesthesia for patients with mediastinal masses. *Can J Anaesth* 1989;36(6):681-8
7. Phillipe B et al Perioperative cardiorespiratory complications in adults with mediastinal mass. *Anesthesiology* 2004;100:826-34

**ACKNOWLEDGEMENTS :**

We thank Dr. Gurushantappa H Yalagachin, Professor in Dept of Surgery, KIMS, Hubli for all the support rendered for this case presentation. ■